

# POSTERIOR PULPECTOMIES:

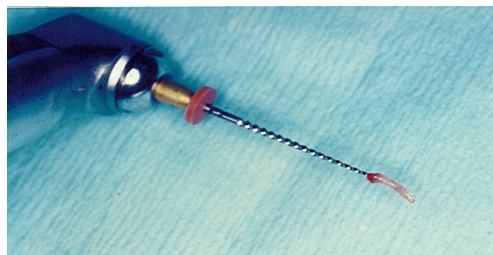
## Using Rotary Files

### Introduction

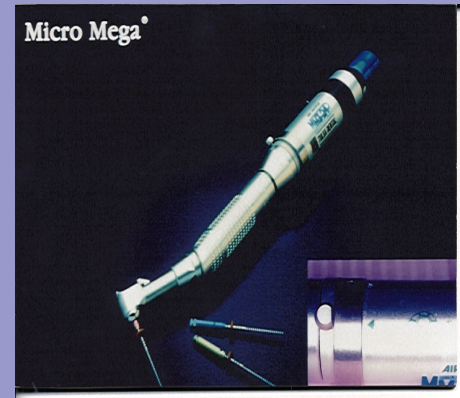This newsletter reviews the use of nickel-titanium rotary files for root canal instrumentation in primary teeth. The pulpectomy technique is described and the advantages and disadvantages of using rotary files are discussed. Specific recommendations for the selection of materials and devices are made.

The pulpectomy procedure for restorable primary teeth is the preferred treatment of infected pulpal tissue in single rooted teeth and in molars with signs of radicular involvement. Prior to the placement of pulpectomy paste, the root canals of primary teeth are shaped and cleaned. This has traditionally been done with endodontic broaches and hand files.

Recently, nickel-titanium rotary files (NT), (ProFile® .04 ISO Rotary Instruments, Dentsply/Tulsa, Tulsa, OK) have been developed for use in endodontics. The flexibility and the instrument design allows the files to closely follow the original root canal path. Studies have consistently shown that root canal preparation in permanent teeth with NT is efficient and effective.<sup>10</sup> The same principles of canal debridement and dentin shaping using NT can be applied to primary teeth. The tortuous and irregular canal walls of primary molars are effectively cleaned with NT since the clockwise motion of the rotary files pulls pulpal tissue and dentin out of the canal as the files are engaged.



NT produces the predefined tapered shape that is built into the instrument design. ProFile® rotary instruments have a .04 taper which is twice that of traditional .02 tapered hand files. This results in a smooth funnel-form preparation that easily accepts pulpectomy paste. Orifice shapers® and GT® files with differing flute designs and rates of taper are available for use in adult endodontics. However, we suggest that the novice clinician begin by using the .04 rotary tapers since they are efficient without undue aggressiveness. An educational video tape is available from Dentsply/Tulsa that describes the technical use of these rotary files. Although specific to permanent teeth, the same principles apply to the primary dentition.



Nickel-titanium rotary files must be driven by a low-speed constant-torque handpiece. The ideal rotational speed is 150-300 rpm. This is too slow for use in a conventional slow-speed handpiece. The Micro Mega® MM324 air-drive handpiece (Geneva, Switzerland) or the Aspetico® electric handpiece (Woodinville, WA) meet this requirement.

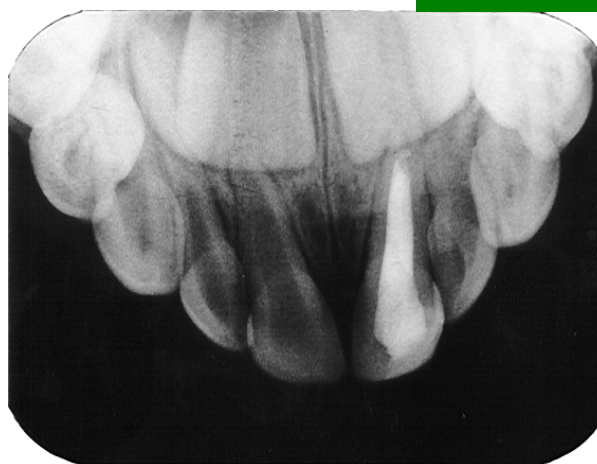## Technique

The pulpectomy procedure begins with a standard access and removal of coronal tissue. An NT is chosen that approximates the canal size. It is inserted into the canal while rotating and is taken to working length as determined on the pretreatment radiograph. Since the apex in primary teeth exits about 1mm. before the radiographic tip, keep the working length 1½-2mm short. The rotating file is withdrawn and cleaned of pulpal tissue and dentinal debris. The canal is cleansed and shaped with sequentially larger files until the last file binds. The preparation is now complete.

It is not necessary to use a "crown down" instrumentation technique in primary teeth since the dentin cuts more easily than in permanent teeth. In primary teeth, care must be taken not to over-instrument as perforations can readily occur in the thin dentinal walls. Apical over-extension of the NT can result in an enlarged apical foramen and cause an overfill of pulpectomy paste. Sterile water, saline or chlorhexidene can be used to keep the canals moist. Instrumenting dry or aggressively can result in broken file tips, especially in the smaller size files. Frequently inspect each file for flute unwinding or distortion and discard immediately. If no flute distortion is detected discard the files after use in five primary teeth. To keep track of file usage, the file shanks can be notched with a bur at the end of each case.

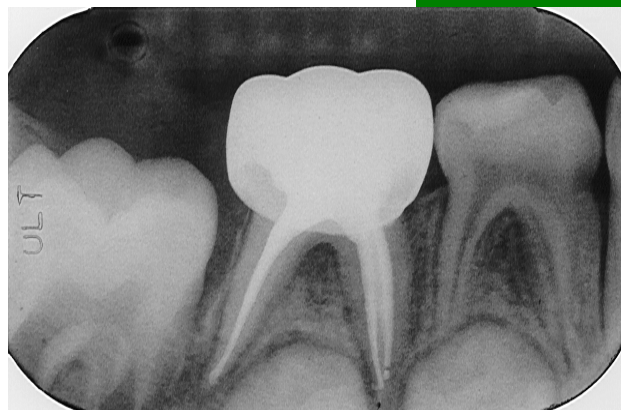After irrigation, the canals are dried and filled with a stiff past of USP zinc oxide and eugenol using a hand file to push the paste just short of the apex. A stiff paste is more easily inserted and decreases the chance of an overfill. Fig 1 and 2 show radiographic examples of completed pulpectomies using the NT instrumentation technique.

Fig 1



Maxillary left primary central incisor shaped with nickel-titanium rotary .04 tapered files and filled with pulpectomy paste.

Fig 2



Mandibular right second primary molar shaped with nickel-titanium rotary .04 tapered files and filled with pulpectomy paste.

### Summary


We have used NT since 1993 and consider this technique a more effective way to debride the uneven walls of primary teeth. In addition, the use of rotary instrumentation is faster than hand files and facilitates a consistently dense fill. The use of rotary instrumentation for primary teeth pulpectomies has proven to be cost effective, faster and has resulted in consistently uniform, predictable fills. The major advantages and disadvantages of this technique are:

#### **Advantages:**

- tissue and debris are more easily and quickly removed
- the nickel-titanium files are flexible allowing easy access to all canals
- prepared canals are funnel shaped resulting in a more predictable uniform paste fill
- NTs are available in a 21mm length

#### **Disadvantages:**

- cost of the low-speed, constant-torque handpiece
- increased cost of NT
- learning the technique (video tape is available from Tulsa)



### References:

1. Pettiette MT, Metzger Z, Phillips C, Trope M. Endodontic complications of root canal therapy performed by dental students with stainless-steel K-files and nickel-titanium hand files. J Endodon 25:230-234,1999.
2. Ottosen SR, Nicholls JI, Steiner JC. A comparison of instrumentation using naviflex and profile nickel-titanium engine-driven rotary instruments. J Endodon 25:457-463,1999.
3. Short JA, Morgan LA, Baumgartner JC. A comparison of canal centering ability of four instrumentation techniques. J Endodon 23:503-507,1997.

### Produced By

Betty Barr, D.M.D.  
Nelle Barr, D.M.D.

5150 West 80th Ave.  
Westminster, CO 80030

Phone: 303-427-1951

[www.ddschild.com](http://www.ddschild.com)

CHILDREN'S DENTISTRY  
A PARTNERSHIP

